



Available online at [www.sciencedirect.com](http://www.sciencedirect.com)

ScienceDirect

journal homepage: [www.elsevier.com/locate/gie](http://www.elsevier.com/locate/gie)



ORIGINAL ARTICLE/ARTICOLO ORIGINALE

# Apical surgery vs apical surgery with simultaneous orthograde retreatment: A prospective cohort clinical study of teeth affected by persistent periapical lesion

*Chirurgia apicale vs Chirurgia apicale con ritrattamento ortogrado simultaneo: studio clinico prospettico di coorte*

Carlo Prati, Arash Azizi\*, Chiara Pirani, Fausto Zamparini, Francesco Iacono, Lucio Montebugnoli, Maria Giovanna Gandolfi

Endodontic Clinical Section, Department of Biomedical and Neuromotor Sciences (DIBINEM), University of Bologna, Bologna, Italy

Received 7 June 2017; accepted 14 March 2018

Available online 3 May 2018

## KEYWORDS

Apical surgery;  
Retreatment;  
Treatment;  
Endodontics;  
MTA.

## Abstract

**Aim:** This prospective clinical study analyzed the 24-month outcome of conventional apical surgery retro-filled with calcium-silicate cement *versus* apical surgery with simultaneous orthograde retreatment by means of clinical and radiographic criteria.

**Materials and methods:** This study included 83 teeth affected by persistent periapical lesions in 68 patients. Mean age was 52 years (median = 51 years; range 19–81 years). Twenty-eight cases were treated with apical surgery, 16 cases with apical surgery with simultaneous orthograde retreatment and 39 cases with orthograde retreatment in previously treated teeth established as control group. Periapical index score (PAI) was used as radiographic criteria. Teeth were examined at 6 months, 1 and 2 years and classified as *healed* (without any symptoms and

\* Corresponding author at: Endodontic Clinical Section, Department of Biomedical and Neuromotor Sciences (DIBINEM), University of Bologna Alma Mater Studiorum, Bologna, Italy.

E-mail: [carlo.prati@unibo.it](mailto:carlo.prati@unibo.it) (C. Prati), [arash.azizi@studio.unibo.it](mailto:arash.azizi@studio.unibo.it) (A. Azizi), [chiara.pirani4@unibo.it](mailto:chiara.pirani4@unibo.it) (C. Pirani), [fausto.zamparini2@unibo.it](mailto:fausto.zamparini2@unibo.it) (F. Zamparini), [francesco.iacono@hotmail.it](mailto:francesco.iacono@hotmail.it) (F. Iacono), [lucio.montebugnoli@unibo.it](mailto:lucio.montebugnoli@unibo.it) (L. Montebugnoli), [mgiovanna.gandolfi@unibo.it](mailto:mgiovanna.gandolfi@unibo.it) (M.G. Gandolfi).

Peer review under responsibility of Società Italiana di Endodonzia.



Production and hosting by Elsevier

<https://doi.org/10.1016/j.gien.2018.03.001>

1121-4171/© 2018 Società Italiana di Endodonzia. Production and hosting by Elsevier B.V. This is an open access article under the CC BY-NC-ND license (<http://creativecommons.org/licenses/by-nc-nd/4.0/>).

**PAROLE CHIAVE**

Chirurgia apicale;  
Ritrattamento;  
Trattamento;  
Endodonzia;  
MTA.

PAI  $\leq 2$ ), *healing* (without any symptoms and PAI = 3) or *diseased* (with symptoms or PAI  $\geq 4$  and not functional) on the basis of radiographic and clinical criteria. At 24 months evaluation, *healed* and *healing* were considered as *success* and *diseased* and *fracture* as *failure*. Multilevel GLM model and an ordered logistic regression as statistical analysis was made with level of significance set at  $p < 0.05$ .

**Results:** Total drop-out was 7% ( $n = 6$ ). After 6–9 months, 6 teeth (3 from apical surgery, 2 from simultaneous treatment and 1 from orthograde retreatment) were extracted for root fracture. Twenty-four-month *success rate* of apical surgery group was 78% ( $n = 17$ ), apical surgery with simultaneous orthograde retreatment presented 81% ( $n = 10$ ) and orthograde retreatment success was 80% ( $n = 24$ ). There was no statistically difference between the groups at 24 months ( $p = 0.890$ ).

**Conclusions:** Both surgical techniques revealed a high percentage of healing, similar to that reported by previous studies. Apical surgery with simultaneous orthograde retreatment showed a faster healing after 12 months comparing to the control group.

© 2018 Società Italiana di Endodonzia. Production and hosting by Elsevier B.V. This is an open access article under the CC BY-NC-ND license (<http://creativecommons.org/licenses/by-nc-nd/4.0/>).

**Riassunto**

**Scopo:** In questo studio sono stati confrontati pazienti trattati con chirurgia apicale convenzionale vs chirurgia apicale con ritrattamento ortogrado simultaneo. Come gruppo controllo, sono stati considerati pazienti sottoposti a ritrattamento ortogrado.

**Materiali e metodi:** Questo studio ha incluso 83 elementi con lesioni periapicali persistente (68 pazienti). Ventotto casi di chirurgia apicale, 16 casi di chirurgia apicale con ritrattamento ortogrado simultaneo e 39 casi di ritrattamento ortogrado non chirurgico come gruppo controllo. L'indice periapicale (PAI) è stato utilizzato come criterio radiografico. Gli elementi sono stati esaminati ogni 6 mesi per 24 mesi e classificati in base a criteri clinici e radiografici come *guarito* (assenza di sintomi e PAI  $\leq 2$ ), *in guarigione* (assenza di sintomi e PAI = 3) e *non guarito* (presenza di sintomi o PAI  $\geq 4$ ). A 24 mesi gli elementi *guariti* e *in guarigione* sono stati classificati come *successo clinico* mentre gli elementi *non guariti* e *fratturati* come *fallimento*. È stata eseguita un'analisi statistica sul modello multilevel GLM e regressione logistica per valutare una possibile differenza significativa tra i gruppi ( $p < 0.05$ ).

**Risultati:** Il drop-out è stato del 7% ( $n = 6$ ). Sei elementi (3 dal gruppo chirurgia apicale, 2 dal gruppo chirurgia apicale con ritrattamento ortogrado simultaneo e 1 dal gruppo ritrattamento ortogrado non chirurgico) sono stati estratti dopo 6-9 mesi per frattura radicolare e sono stati considerati come fallimento. Nel gruppo di chirurgia apicale si è osservato un successo clinico a 24 mesi del 78% ( $n = 17$ ), nel gruppo chirurgia apicale con ritrattamento ortogrado simultaneo dell' 81% ( $n = 10$ ) e nel gruppo ritrattamento ortogrado non chirurgico dell' 80% ( $n = 24$ ).

**Conclusioni:** Entrambe le tecniche chirurgiche hanno mostrato un'alta percentuale di successo a 24 mesi. Non ci sono state differenze significative tra i trattamenti ( $p = .890$ ) a 24 mesi. È stato osservato una guarigione più rapida nel gruppo di chirurgia apicale con ritrattamento ortogrado simultaneo.

© 2018 Società Italiana di Endodonzia. Production and hosting by Elsevier B.V. Cet article est publié en Open Access sous licence CC BY-NC-ND (<http://creativecommons.org/licenses/by-nc-nd/4.0/>)

**Introduction**

The aim of orthograde retreatment is the elimination of necrotic tissue, bacteria and infected obturation material such as gutta-percha and cements from root canal and seal of the canals to prevent re-infection and allow healing.<sup>1</sup> Preparing root canals to the apical foramina<sup>2</sup> or using a patency file<sup>3</sup> may clean most of the apical portion of the main canal, but bacteria are still likely to remain in lateral and accessory canals or in apical ramifications<sup>4</sup> that remain un-instrumented or out of the reach of irrigants. In specific cases when bacteria colonize the apical ramifications of the canal or in presence of extraradicular infection, a surgical procedure

effectively removes the infected site and enhances chances of healing.<sup>5</sup> However, in the majority of teeth in which bacteria colonize within the entire root canal system, root-end filling might not effectively prevent persistence or recurrence of apical periodontitis after surgical procedure,<sup>5</sup> hence a simultaneous orthograde therapy with apical surgery would eliminate the infection and prevent reinfection.<sup>6</sup> As orthograde retreatment is performed simultaneously with apical surgery, coronal and middle portions of the root canal system are also cleaned thoroughly.<sup>7,8</sup> Therefore, the present study compared results of two different surgical approaches, with and without simultaneous orthograde retreatment. As control group conventional orthograde retreatment was considered.

## Materials and methods

The study was conducted in full accordance with the ethical principles, including the Declaration of Helsinki.<sup>9</sup> This report was written according to Consolidated Standards of Reporting trials guidelines for reporting clinical trials.<sup>10</sup>

### Patient population

This study was conducted in the Department of Endodontic, Alma Mater Studiorum University of Bologna. It considered 83 teeth in 68 patients ( $M = 35$ ,  $F = 48$ ; mean age = 52; median = 51 years; range 19–81 years). Table 1 illustrates teeth distribution according to gender, age and treatments.

Inclusion criteria were previous root canal treatment, periodontal lesion of strictly endodontic origin with or without clinical signs or symptoms such as swelling and sinus tract and a minimum follow-up of 24 months. Only cooperative patients without any compromised medical history and use of bisphosphonates were included. Exclusion criteria were class II mobility or greater, horizontal and vertical fractures, perforations, local anatomical limits and inadequate periodontal support.

Criteria for inclusion of teeth in 3 groups were based on 2 different factors: lesion diameter and prosthetic restoration. When a lesion diameter was  $>5$  mm, in presence or absence of prosthetic restoration, tooth was subjected respectively to apical surgery or apical surgery with simultaneous orthograde retreatment. Instead if a lesion diameter was  $\leq 5$  mm, tooth was subjected to orthograde retreatment independently from prosthetic restoration.

### Treatments

In apical surgery group a preoperative periapical radiograph (Ultraspeed, Carestream, USA) of the tooth was captured, the tooth anaesthetized with 2% mepivacaine (Carboplyina, Molteni, Scandicci, Italy). A full-thickness mucoperiosteal flap was raised. Then osteotomy with high speed water-cooled diamond burs (Intensiv, Grancia, Switzerland) mounted on a high-speed water-cooled handpiece (Castellini-Anthos, Bologna, Italy) has been done. After hemostasis, affected roots were resected for 2–3 mm with a diamond bur. Root-end cavities were prepared and filled with a hydraulic calcium silicate

cement. Wound was closed using multiple interrupted sutures with Vicryl 3.0 (Johnson & Johnson, Spreitenbach, Switzerland). In different cases Coe-Pak (GC, Fuji, Japan) as a non-eugenol surgical dressing was used. Patient was recalled after 7–14 days. In this session, in case Coe-Pack was used, it was removed, wound was controlled, sutures were removed and a control X-ray was taken.

In apical surgery with simultaneous orthograde retreatment group a preoperative periapical radiograph of the tooth was captured, the tooth anaesthetized with 2% mepivacaine (Carboplyina, Molteni, Scandicci, Italy) and isolated with rubber dam (Hygienic Dental Dam, Coltène Waledent, Cuyahoga Falls, OH, USA). Straight-line access was prepared with a high-speed, water-cooled diamond bur (Intensiv, Grancia, Switzerland) mounted on a high-speed water-cooled handpiece (Castellini-Anthos, Bologna, Italy). After preliminary scouting of canals with size 10 K-files (Dentsply Sirona, Ballaigues, Switzerland), working length (WL) was established with an electronic apex locator (Root ZX, Morita, Tokyo, Japan) and confirmed radiographically. Canals were instrumented in a stepdown sequence with the coronal third enlarged with size 4-3-2 Gates-Glidden drills (Dentsply Sirona) and the middle and apical thirds instrumented by hand with K-files (Dentsply Sirona) with 1 mm increments to size 20 to 45 at WL in a step-back technique. Canals were intermittently irrigated with 5 to 10 mL of 5% NaOCl (Nicolor 5, Ogna, Muggiò, Italy), cleaned with Endosolv (Septodont, Cedex, France) and finally flushed with 1 to 3 mL of 10% EDTA (Tubuliclean, Ogna). Canals were filled with vertical compaction of guttaperca (Hygienic, Coltène, Germany) and an endodontic sealer. Then Rubber dam was removed and apical surgery as described earlier was performed. A final X-ray was taken. In different cases Coe-Pak (GC, Fuji, Japan) as a non-eugenol surgical dressing was used. Patient was recalled after 7–14 days. In this session, in case Coe-Pack was used, it was removed, wound was controlled, sutures were removed and a control X-ray was taken.

In orthograde retreatment the procedures were standardized following Pirani et al.<sup>11</sup> Canals were instrumented in a stepdown sequence with the coronal third enlarged with size 4-3-2 Gates-Glidden drills (Dentsply Sirona) and the middle and apical thirds instrumented by hand with K-files (Dentsply Sirona) and obturated with Thermafil (Tulsa Dental Products, Tulsa, OK) and AH Plus sealer (Dentsply DeTrey, Konstanz, Germany).

### Follow-up

A radiographic examination was performed prior to intervention, 1 week after treatment, 1 month and then every 6 months up to 24 months. Radiographs were taken with X-ray films using paralleling technique in the standardized position.

### Assessment of clinical success

Clinical success was defined on the base of clinical and radiographic criteria. Clinical criteria were presence of symptoms (swelling, sinus tract) or other signs of infection and/or normal functioning of the tooth. Radiographic criteria were examined according with periapical index.<sup>12</sup> Teeth free from symptoms and  $PAI \leq 2$  were classified as *healed*. Teeth

**Table 1** Teeth distribution.

Distribution and number of the teeth		
Gender	Males	35
	Females	48
Age	18–30	9
	31–40	15
	41–50	16
	51–60	14
	>60	29
Treatments	Apical surgery	28
	Apical surgery with simultaneous orthograde retreatment	16
	Orthograde retreatment	39
Total		83

**Table 2** Final clinical outcome. Clinical success rate also considered fractures of 3 teeth in apical surgery group, 2 teeth in apical surgery with simultaneous orthograde retreatment group and 1 tooth in orthograde retreatment group. Success was defined when a tooth was considered *healed* or *healing* and failure when *diseased* or *fractured*. Final clinical outcome at 24 months for apical surgery was 78%, for apical surgery with simultaneous orthograde retreatment was 81% and for orthograde retreatment was 80%.

	Clinical outcome					
	Success % (n)			Failure % (n)		
	Healed	Healing	Total	Diseased	Fractured	Total
Apical surgery (n = 26)	67% (17)	11% (3)	78% (20)	11% (3)	11% (3)	22% (6)
Apical surgery with simultaneous orthograde retreatment (n = 15)	68% (10)	13% (2)	81% (12)	6% (1)	13% (2)	19% (3)
Orthograde retreatment (n = 36)	66% (24)	14% (5)	80% (29)	17% (6)	3% (1)	20% (7)

without any symptoms and PAI = 3 in which the lesion is reduced were classified as *healing* and teeth with symptoms or PAI  $\geq 4$  were classified as *diseased*. At 24 months evaluation, *healed* and *healing* were considered as *success* and *diseased* and *fracture* as *failure*.

### Statistical analysis

Multilevel GLM model was fitted to evaluate the existence of any significant difference regarding treatments, follow-up times (baseline, 6 months, 12 months and 24 months), and the interaction between treatments and time frames; tooth type was added to the model as covariate. An ordered logistic regression was fitted to evaluate any significant difference between treatments as final outcome. *p* value was previously set at 0.05.

### Results

Six teeth in 6 patients were excluded for lack of follow-up (drop-out = 7%), so that 77 teeth (62 patients) were included in the study. Results at 24 months are shown in Table 2. The PAI score and the presence of pathological signs and/or symptoms were recorded at follow-ups (Figs. 1–3). Six teeth were extracted for root fracture 3 to 12 months after the treatment, 3 teeth in apical surgery group (one central upper incisor, two lateral upper incisors), two teeth in apical surgery with simultaneous orthograde retreatment group (one central upper incisor and one lateral upper incisor) and one tooth in conventional orthograde retreatment group (first upper premolar).

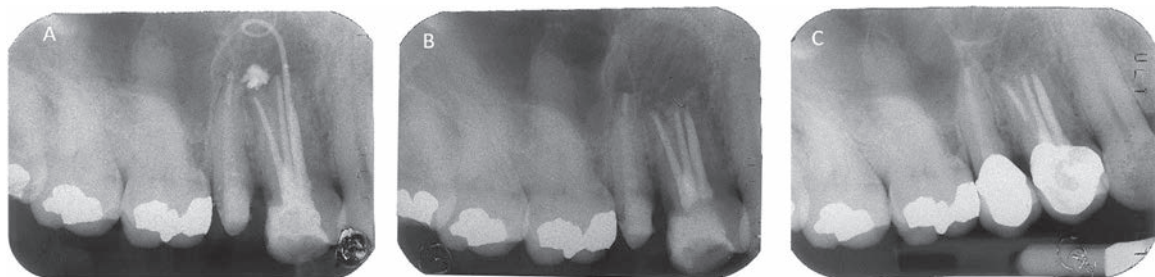A statistically significant difference between apical surgery with simultaneous orthograde retreatment and orthograde retreatment was observed at 12 months ( $p = 0.025$ ). Apical surgery with simultaneous orthograde retreatment showed faster healing compared to conventional orthograde retreatment (Fig. 4). It should be mentioned that apical surgery with simultaneous retreatment and orthograde retreatment at 24 months were just at the limit of statistically significant difference ( $p = 0.069$ ).

### Discussion

According to data from the present study, apical surgery with simultaneous orthograde retreatment showed a statistically higher healing rate ( $p = 0.025$ ) at 12 months, compared to conventional orthograde retreatment.

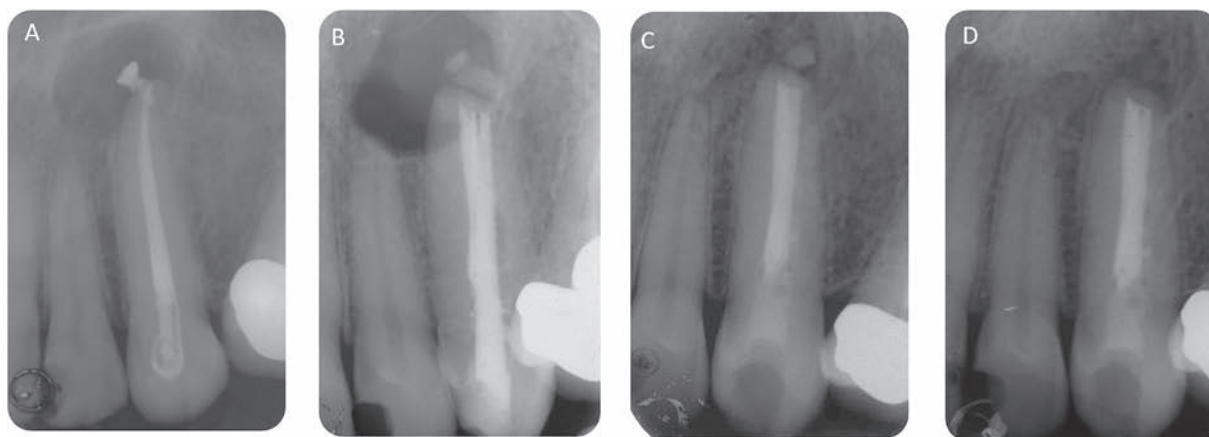
These results are in agreement with a previous Cochrane systematic review<sup>13</sup> which analyzed 3 different randomized controlled trials.<sup>14–16</sup> Results of this study confirmed also a meta-analysis,<sup>17</sup> where orthograde retreatment over a 2 years follow-up time showed a lower success rate compared to apical surgery, but considered an orthograde retreatment more effective over a 4 years follow-up time.<sup>17</sup> Hence, a longer follow-up (4 years) is required to evaluate results before final classification.<sup>18</sup> In a past systematic review<sup>19</sup> apical surgery with simultaneous orthograde retreatment showed a higher success compared to apical surgery and orthograde retreatment separately.

After the introduction of microsurgical principles and new materials for apical obturation in endodontic surgery (i.e. Calcium Silicate materials) healed rates of apical surgery with root-end filling improved.<sup>20</sup> Calcium silicate demon-

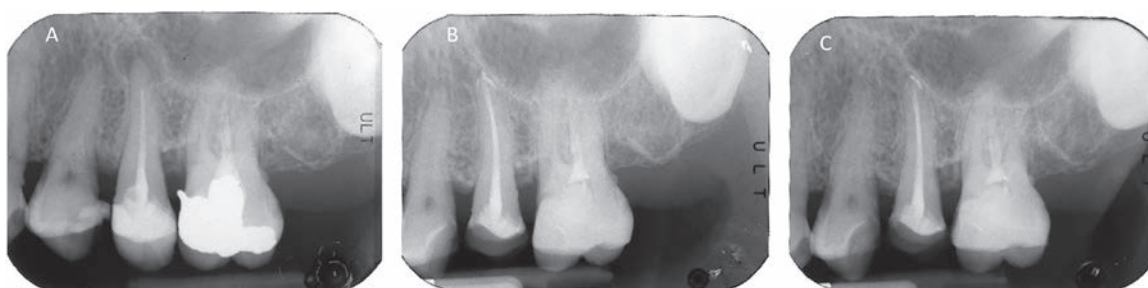

**Figure 1** (A) A preoperative radiograph of a maxillary first premolar with a periradicular lesion. (B) A postoperative radiograph of tooth underwent apical surgery. (C) The radiograph taken at the 2-year recall exhibits a complete resolution of the periradicular endodontic lesion. The tooth is classified as healed.

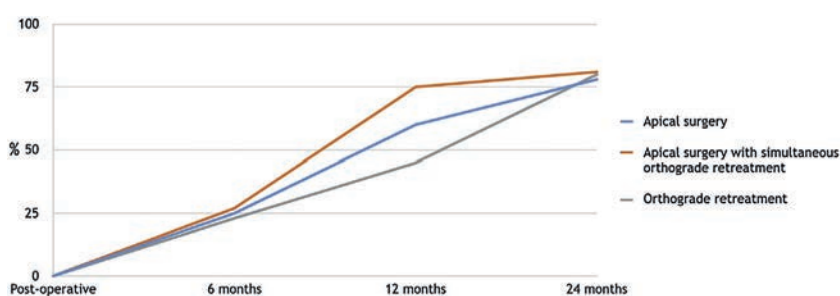




**Figure 2** (A) A preoperative radiograph of a maxillary canine with a periradicular lesion. (B) A postoperative radiograph of tooth underwent apical surgery with simultaneous orthograde retreatment. (C) The radiograph taken at the 1-year recall. (D) The radiograph taken at the 2-year recall. The tooth is classified as healed.



**Figure 3** (A) A preoperative radiograph of a first mandibular molar with a periradicular lesion. (B) The radiograph taken at the 6-month recall of tooth underwent orthograde retreatment. (C) The radiograph taken at the 2-year recall. The tooth is classified as healed.



**Figure 4** Percentages of healing lesions with different treatments over time. Different healing percentages are noticeable between apical surgery with simultaneous retreatment and orthograde retreatment at one year with statistically significant difference ( $p < 0.025$ ), but final healing percentages at 24 months do not present any statistically significant difference among any of the treatments.

strated good biocompatibility,<sup>21</sup> antimicrobial properties,<sup>22</sup> hydrophilicity,<sup>23</sup> sealing ability,<sup>24</sup> biointeractive and bioactive features.<sup>25,26</sup>

In the present study 5 teeth subjected to apical surgery and apical surgery with simultaneous orthograde retreatment were extracted for root fracture which were not statistically analyzed but were considered as failures in survival rates. This fact may be interesting as reviewed by Ng et al.<sup>27</sup> amongst 15 studies only one<sup>28</sup> included extractions and

retreatments in the failure category.<sup>29</sup> Calcium silicate cement showed in vitro a 1.04% expansion during fluid contamination (i.e. blood).<sup>30</sup> This expansion may be an initial cause for root crack during apical surgery.

In this study lesions size was a criteria for treatment selection. In small lesions resident progenitor cells/stem cells might be capable of restoring damage periapical tissue but in large lesions it will not occur and the defect will heal by fibrous connective tissue repair.<sup>31–33</sup>

Different flap techniques (papilla base and sulcular incision) is introduced in apical surgery but there was no statistically different between these groups in term of soft tissue modifications.<sup>34</sup>

In this study all teeth were endodontically treated before the surgery but also in specific cases such as restorations and dystrophic calcification apical surgery could be as the first treatment option.<sup>35</sup> A recent long term study shows high percentage of healing in endodontic treatments but few information is available on long-term outcome of apical surgery.<sup>36</sup>

## Conclusions

Both surgical techniques and orthograde retreatment revealed a high percentage of healing.

The statistically significant difference at 12 months between apical surgery with simultaneous orthograde retreatment and orthograde retreatment showed a faster healing rate in the first group. This can be explained by slower healing dynamics in the orthograde retreatment in which the lesion is not radically removed. Anyway there was not any statistically significant difference between the groups at 24 months.

## Conflict of interest

The authors have no conflicts of interest to declare.

## References

- Saunders WR. Considerations in the revision of previous surgical procedures. *Endod Top* 2005;11:206–18.
- Buchanan LS. The standardized-taper root canal preparation – Part 1. Concepts for variably tapered shaping instruments. *Int Endod J* 2000;33:516–29.
- Cailleteau JG, Mullaney TP. Prevalence of teaching apical patency and various instrumentation and obturation techniques in United States dental schools. *J Endod* 1997;23:394–6.
- Nair PN, Henry S, Cano V, Vera J. Microbial status of apical root canal system of human mandibular first molars with primary apical periodontitis after “one-visit” endodontic treatment. *Oral Surg Oral Med Oral Pathol Oral Radiol Endod* 2005;99:231–52.
- Friedman S. Treatment outcome: the potential for healing and retained function. In: Ingle JI, editor. *Endodontics*. 6th ed. Hamilton, Ontario: BC Decker; 2008.
- Molven O, Olsen L, Kerekes K. Scanning electron microscopy of bacteria in the apical part of root canals in permanent teeth with periapical lesions. *Endod Dent Traumatol* 1991;7:226–9.
- Reit C, Hirsch J. Surgical endodontic retreatment. *Int Endod J* 1986;19:107–12.
- Rubinstein RA, Kim S. Short-term observation of the results of endodontic surgery with the use of a surgical operation microscope and super-EBA as root-end filling material. *J Endod* 1999;25:43–8.
- World Medical Association Declaration of Helsinki: ethical principles for medical research involving human subjects. *JAMA* 2013;310:2191–4.
- Vandenbroucke JP, von Elm E, Altman DG, Gøtzsche PC, Mulrow CD, Pocock SJ, et al. Strengthening the Reporting of Observational Studies in Epidemiology (STROBE): explanation and elaboration. *PLoS Med* 2007;4:1628–54.
- Pirani C, Friedman S, Gatto MR, Iacono F, Tinarelli V, Gandolfi MG, Prati C. Survival and periapical health after root canal treatment with carrier-based root fillings: Five-year retrospective assessment. *Int Endod J* 2017;51:178–88.
- Ørstavik D, Kerekes K, Eriksen HM. The periapical index: a scoring system for radiographic assessment of apical periodontitis. *Endod Dent Traumatol* 1986;2:20–34.
- Del Fabbro M, Taschieri S, Testori T, Francetti L, Weinstein R. Surgical versus non-surgical endodontic re-treatment for periradicular lesions. *Cochrane Database Syst Rev* 2007;CD005511.
- Danin J, Strömberg T, Forsgren H, Linder LE, Ramsköld LO. Clinical management of nonhealing periradicular pathosis surgery versus endodontic retreatment. *Oral Surg Oral Med Oral Pathol Oral Radiol Endod* 1996;82:213–7.
- Kvist T, Reit C. Results of endodontic retreatment: a randomized clinical study comparing surgical and nonsurgical procedures. *J Endod* 1999;25:814–7.
- Kvist T, Reit C. Postoperative discomfort associated with surgical and nonsurgical endodontic retreatment. *Endod Dent Traumatol* 2000;16:71–4.
- Torabinejad M, Corr R, Handysides R, Shabahang S. Outcomes of nonsurgical retreatment and endodontic surgery: a systematic review. *J Endod* 2009;35:930–7.
- European Society of Endodontology. Quality guidelines for endodontic treatment. *Int Endod J* 1994;27:115–24.
- Hepworth MJ, Friedman S. Treatment outcome of surgical and non-surgical management of endodontic failures. *J Can Dent Assoc* 1997;63:364–71.
- Von Arx T. Failed root canals: the case for apicoectomy (Periradicular Surgery). *J Oral Maxil Surg* 2005;63:832–7.
- Mitchell PJ, Pitt Ford TR, Torabinejad M, McDonald F. Osteoblast biocompatibility of mineral trioxide aggregate. *Biomaterials* 1999;20:167–73.
- Torabinejad M, Hong CU, McDonald F, Pitt Ford TR. Physical and chemical properties of a new root-end filling material. *J Endod* 1995;21:349–53.
- Torabinejad M, Higa RK, McKendry DJ, Pitt Ford TR. Dye leakage of four root end filling materials: effects of blood contamination. *J Endod* 1994;20:159–63.
- Gandolfi MG, Sauro S, Mannocci F, Watson TF, Zanna S, Capoferri M, et al. New tetrasilicate cements as retrograde filling material: an in vitro study on fluid penetration. *J Endod* 2007;33:742–5.
- Gandolfi MG, Taddei P, Tinti A, Prati C. Apatite-forming ability (bioactivity) of ProRoot MTA. *Int Endod J* 2010;43:917–29.
- Gandolfi MG, Taddei P, Modena E, Siboni F, Prati C. Biointeractivity-related versus chemi/physisorption-related apatite precursor-forming ability of current root end filling materials. *J Biomed Mater Res B Appl Biomater* 2013;101:1107–23.
- Ng YL, Mann V, Rahbaran S, Lewsey J, Gulabivala K. Outcome of primary root canal treatment: systematic review of the literature – Part 1. Effects of study characteristics on probability of success. *Int Endod J* 2007;40:921–39.
- Cheung GS. Survival of first-time nonsurgical root canal treatment performed in a dental teaching hospital. *Oral Surg Oral Med Oral Pathol Oral Radiol Endod* 2002;93:596–604.
- Wu MK, Shemesh H, Wesselink PR. Limitations of previously published systematic reviews evaluating the outcome of endodontic treatment. *Int Endod J* 2009;42:656–66.
- Gandolfi MG, Iacono F, Agee K, Siboni F, Tay F, Pashley DH, et al. Setting time and expansion in different soaking media of experimental accelerated calcium-silicate cements and Pro-Root MTA. *Oral Surg Oral Med Oral Pathol Oral Radiol Endod* 2009;108:39–45.
- Tsesis I, Rosen E, Tamse A, Taschieri S, Del Fabbro M. Effect of guided tissue regeneration on the outcome of surgical endodontic treatment: a systematic review and meta-analysis. *J Endod* 2011;37:1039–45.

32. Grzesik WJ, Narayanan AS. Cementum and periodontal wound healing and regeneration. *Crit Rev Oral Biol Med* 2002;13:474–84.
33. Andreasen JO, Rud J. Modes of healing histologically after endodontic surgery in 70 cases. *Int J Oral Surg* 1972;1:148–60.
34. Taschieri S, Del Fabbro M, Francetti L, Perondi I, Corbella S. Does the papilla preservation flap technique induce soft tissue modifications over time in endodontic surgery procedures? *J Endod* 2016;42:1191–5.
35. Jonasson P, Lennholm C, Kvist T. Retrograde root canal treatment: a prospective case series. *Int Endod J* 2017;50(6):515–21.
36. Prati C, Pirani C, Zamparini F, Gatto MR, Gandolfi MG. A 20-year historical prospective cohort study of root canal treatments. A Multilevel analysis. *Int Endod J* 2018. <http://dx.doi.org/http://dx.doi.org/10.1111/iej.12908> [In press].