

Comparative Evaluation of the Ability of Four Reciprocating System to Remove Obturation Material in Maxillary First Molar: an In vitro Study

Aim: To evaluate and compare the ability of four reciprocating systems—Reciproc Blue, WaveOne Gold, MicroMega One RECI, and EdgeOne Fire—to remove obturation material using micro-computed tomography (micro-CT).

Methods: Twenty-four extracted maxillary first molars featuring Vertucci Type I mesiobuccal canals were shaped and obturated using gutta-percha with AH Plus sealer. After aging, the specimens were randomly divided into four groups and retreated with the corresponding reciprocating systems. Micro-CT imaging measured the initial obturation volume, volume of residual filling material volume, and percentage of residual material across the total, middle, and apical thirds. Operative time was also documented. Statistical analysis employed one-way ANOVA with post-hoc Tukey's test.

Results: Baseline obturation volumes were comparable among groups. Post-retreatment analysis revealed significant differences in the apical third ($p = 0.005$). Reciproc Blue showed the least residual volume ($0.48 \pm 0.56 \text{ mm}^3$), followed by MicroMega One RECI ($0.52 \pm 0.34 \text{ mm}^3$) and WaveOne Gold ($0.99 \pm 0.47 \text{ mm}^3$), while EdgeOne Fire demonstrated the highest residual volume ($1.43 \pm 0.41 \text{ mm}^3$). Percentage residuals followed similar trends but were not statistically significant ($p > 0.05$). Operative time differed significantly ($p < 0.001$), with EdgeOne Fire being the slowest.

Conclusion: Complete removal was not achieved by any system. Reciproc Blue and MicroMega One RECI were most efficient in the apical third, whereas EdgeOne Fire was least effective and significantly slower.

Hari Prasad Sundaramoorthy¹
Dhanavel Chakravarthy^{2*}
Vijaya Raja Selvapandian³
Revathi Ramasamy⁴,
Jency Abarna Santhiyaguroopan⁵
Soundarya Senthilkumar⁶

¹Doctor, Postgraduate Student, Department of Conservative Dentistry and Endodontics, Indira Gandhi Institute of Dental Sciences, Sri Balaji Vidyapeeth, Puducherry, India

² Doctor, Professor and Head, Department of Conservative Dentistry and Endodontics, Indira Gandhi Institute of Dental Sciences, Sri Balaji Vidyapeeth, Puducherry, India

³Doctor, Associate Professor, Department of Conservative Dentistry and Endodontics, Indira Gandhi Institute of Dental Sciences, Sri Balaji Vidyapeeth, Puducherry, India

⁴ Doctor, Assistant Professor, Department of Conservative Dentistry and Endodontics, Indira Gandhi Institute of Dental Sciences, Sri Balaji Vidyapeeth Puducherry, India

⁵Doctor, Postgraduate Student, Department of Conservative Dentistry and Endodontics, Indira Gandhi Institute of Dental Sciences, Sri Balaji Vidyapeeth, Puducherry, India

⁶Doctor, Postgraduate Student, Department of Conservative Dentistry and Endodontics, Indira Gandhi Institute of Dental Sciences, Sri Balaji Vidyapeeth, Puducherry, India

*Corresponding author

Received 2026, February 23

Accepted 2026, March 20

KEYWORDS Endodontic, Micro-CT, retreatment, root canal, Root canal filling material.

Corresponding Authors*

Dhanavel Chakravarthy, Dr., Professor and Head, Department of Conservative Dentistry and Endodontics, Indira Gandhi Institute of Dental Sciences, Sri Balaji Vidyapeeth, Puducherry, India | 19dhanavel@gmail.com |

Peer review under responsibility of Società Italiana di Endodonzia

10.32067/GIE.2026.554

Società Italiana di Endodonzia. Production and hosting by Helyx srl on behalf of Tecniche Nuove. This is an open access article under the CC BY-NC-ND license (<http://creativecommons.org/licenses/by-nc-nd/4.0/>).



Introduction

Non-surgical retreatment remains the preferred therapeutic option for failed endodontic therapy, as it enables preservation of the natural dentition while addressing persistent or recurrent periapical pathology. Failures often arise from missed anatomy, incomplete biomechanical preparation, inadequate obturation, coronal leakage, or degradation of the sealer interface (1,2). The primary objective of retreatment is to regain patency of the apical foramen, remove residual obturation materials, and facilitate effective disinfection, thereby creating conditions favourable for three-dimensional re-obturation and long-term periapical healing(3,4). Conventional hand instruments and rotary retreatment files have been used for this purpose; however, they are often time-consuming and may leave considerable remnants. In recent years, reciprocating single file systems have gained popularity compared to rotary systems due to their simplicity, reduced procedural time, and enhanced safety(5). Among these, Reciproc Blue, WaveOne Gold, MicroMega One RECI, and EdgeOne Fire represent contemporary reciprocating systems with distinct metallurgical properties and cross sectional geometries. Comparative data on their retreatment performance remain limited, and most available evidence focuses on canal shaping rather than obturation removal. Micro-computed tomography (micro-CT) provides a non-invasive, gold standard approach for three-dimensional volumetric analysis of endodontic obturation quality(6). Therefore, this study aimed to evaluate and compare the efficacy and efficiency of four reciprocating file systems—Reciproc Blue, WaveOne Gold, MicroMega One RECI, and EdgeOne Fire—in removing obturating material from the mesiobuccal canals of maxillary first molars using micro-computed tomography (micro-CT).

Materials and Methods

Study design & Ethical Approval

The study protocol received approval from the Institutional Research Ethics Committee (register No. IGIDSIEC-2023NRP180PGHSCDE). The study samples consisted of extracted human maxillary first molars, both carious and non-carious, collected with informed patient consent.

Sample Selection

Teeth were thoroughly rinsed under running tap water and stored in 0.9% normal saline (Fresenius Kabi India Pvt. Ltd., Pune, India) until use. Inclusion criteria comprised permanent maxillary molars extracted for periodontal reasons or gross decay, with Vertucci type I and mature root apex. Teeth with calcification, immature apices, prior endodontic treatment, resorption, coronal or radicular separation, root fractures, or the presence of a second mesiobuccal canal (MB2) were excluded.

Sample Size calculation and Group Allocation

The sample size was calculated using G*Power software version 3.1.9.4 (Heinrich Heine University, Düsseldorf, Germany). The calculation was based on the primary outcome variable, the amount of remaining filling material, and the statistical test assumed was one-way analysis of variance (ANOVA) for fixed effects with an omnibus comparison among four groups. An effect size (f) of 0.79, derived from the study by Cecagno FL et al.(7), was used with a significance level (α) of 0.05 and statistical power ($1-\beta$) of 0.80. The analysis indicated a minimum total sample size of 24 specimens, corresponding to six teeth per group. Accordingly, 24 teeth were included and randomly allocated into four groups after biomechanical preparation and obturation.

- Group 1: Reciproc Blue (25/.08) (VDW, Munich, Germany),
- Group 2: WaveOne Gold (25/.07)



- (Dentsply Maillefer, Ballaigues, Switzerland),
- Group 3: MicroMega One RECI (25/.06) (Coltene/MicroMega, Besançon, France), and
 - Group 4: EdgeOne Fire (25/.07) (EdgeEndo, New Mexico, USA).

Each sample was randomly numbered from 1 to 24 and cleaned of residual soft tissues, bone fragments, stains, and calculus using an ultrasonic scaler (Woodpecker Dental Ultrasonic Scaler UDS-P, China).

Sample Preparation and Pre-Operative Micro-CT Analysis

For sample preparation, the mesiobuccal root was sectioned at the cementoenamel junction using a diamond disc, and canal patency was confirmed under a dental operating microscope. Biomechanical preparation was performed with WaveOne Gold Primary (25/.07), followed by obturation using WaveOne Gold Primary gutta-percha cones with AH Plus sealer. Excess material was removed with a heated finger plugger. Pre-operative micro-CT scans were obtained using a SkyScan 1273 device (Bruker-microCT, Kontich, Belgium) at 10 µm pixel size, 100 kV, 100 µA, with 180° rotation, a rotation step of 0.4°, camera exposure time of 1,400 ms, and frame averaging of 3. Reconstructions were performed using N-Recon v1.6.3, CTAn v1.12, and CTVol software, with axial sections generated along the long axis of the tooth.

Post-Operative Micro-CT Analysis

For retreatment, samples were assigned to their respective groups. A gutta-percha solvent Endosolv R, (Septodont, Paris, France) was applied, and the designated reciprocating file system was used for removal of filling material. All files were operated in a 6:1 contra-angle handpiece attached to an X-Smart Plus endomotor (Dentsply Maillefer, Ballaigues, Switzerland). The WaveOne Gold group was operated under the WaveOne Gold setting, while the other groups used the Reciproc All setting. Retreat-

ment was continued until the working length was achieved and no filling material was visible on the file flutes, verified under a dental operating microscope at 3.5x magnification, and procedures were carried out by a single experienced operator to reduce operator-related variability. The procedure time was recorded using a digital chronometer, starting at the beginning of obturation removal and ending after completion of reinstrumentation. Radiovisioigraphy was performed to confirm removal, and post-operative micro-CT scans were obtained using the same parameters as the pre-operative scans. Segmentation of dentin and filling materials was performed using CTAn software based on grayscale threshold values.

Micro-CT evaluation focused on volumetric analysis of the apical 3 mm from the working length and the middle 3 mm of the canal, corresponding to approximately 1,000 slices per sample. The micro-CT analysis was performed by a single blinded examiner who was unaware of the experimental groups. The percentage of remaining filling material (RFM) was calculated using the formula: $RFM (\%) = \text{Volume of remaining filling material} / \text{Volume of original filling material} \times 100$.

Statistical Analysis of Data

Normality of data distribution was evaluated using the Shapiro–Wilk test. Intergroup differences in the mean residual filling material and retreatment time among the four reciprocating systems were assessed using one-way analysis of variance (ANOVA). Post hoc pairwise comparisons were conducted with Tukey's test. P value of less than 0.05 was considered statistically significant. All statistical analyses were carried out using SPSS Version 26.0 (IBM Corp., Armonk, NY, 2019).

Results

The comparison of baseline obturation volumes, residual filling material after retreatment, and percentage of residual

Table 1
Comparison of Residual Filling Material Across Root Canal Portions Using Four Reciprocating Systems

Table 2
Time taken for retreatment in seconds

volume across apical, middle, and total canal regions is summarized in Table 1. At baseline, no statistically significant differences were observed among the four groups in any canal portion (apical: $p = 0.082$; middle: $p = 0.110$; total: $p = 0.726$), confirming effective standardization of canal preparation and obturation. Following retreatment, a significant difference was detected in the apical third ($p = .005$), while the middle ($p = .070$) and total canal regions ($p = 0.067$) showed no statistical differences. Tukey's post hoc test indicated that EdgeOne Fire was significantly different from Reciproc Blue and MicroMega One RECI, whereas WaveOne Gold did not differ from any group. Percentage analysis revealed similar trends, with Reciproc Blue and MicroMega One RECI consistently showing the lowest residual percentages and EdgeOne Fire the highest, though these differences were not statistically significant (apical: $p = 0.070$; middle: $p = 0.202$; total: $p = 0.097$). Overall, the

apical third was the most discriminative region, with EdgeOne Fire leaving significantly more residual material compared to Reciproc Blue and MicroMega One RECI.

The operative times are summarized in Table 2. A statistically significant difference was identified among the groups ($p < 0.001$). Tukey's post hoc analysis revealed that EdgeOne Fire required significantly more time compared to Reciproc Blue, WaveOne Gold, and MicroMega One RECI, whereas no significant differences were observed among the remaining three systems. Figure 1 shows Three-dimensional micro-CT reconstructions of root canals before and after instrumentation using different reciprocating file systems. Pre-operative scans (red) illustrate the obturation material, while post-operative scans (green) depict the residual obturation material following instrumentation with Reciproc Blue, WaveOne Gold, MicroMega One RECI, and EdgeOne Fire systems.

Parameter (Obturation Volume)	Root canal portion	Reciproc Blue	WaveOne Gold	MicroMega One RECI	Edge One Fire	F**	Effect size**	p value**
Total	Apical	8.50±3.98	10.25±1.39	9.89±1.43	12.37±1.97	2.580	0.279	.082
	Middle	16.73±5.04	20.91±2.62	23.97±5.69	24.69±8.57	2.282	0.255	.110
	Total	87.10±11.88	89.91±10.85	90.08±8.51	94.16±11.31	0.441	0.062	.726
After retreatment	Apical	0.48±0.56 ^a	0.99±0.47 ^a	0.52±0.34 ^a	1.43±0.41 ^b	5.767	0.464	.005*
	Middle	0.79±0.62	0.88±0.55	0.63±0.35	1.52±0.73	2.742	0.291	.070
	Total	2.23±1.19	2.48±0.83	2.38±0.71	3.66±1.03	2.787	0.295	.067
Percent of residual volume	Apical	4.28±4.04	10.19±6.06	5.44±3.97	10.21±4.06	2.738	0.291	.070
	Middle	4.12±2.89	4.32±2.81	2.81±1.84	7.09±5.17	1.685	0.202	.202
	Total	2.53±1.12	2.75±0.89	2.65±0.82	3.93±1.22	2.412	0.266	.097

All Values are presented in Mean±SD * $p < .05$ considered significant. **Derived from One Way ANOVA. Values with different superscript letters differ significantly (Tukey's post hoc test, $p < .05$). In the apical third, EdgeOne Fire (^b) was significantly different from Reciproc Blue (^a) and MicroMega One RECI (^a). WaveOne Gold (^a) did not differ significantly from any group.

Table 1

Group	Mean±SD	F	Effect size	p value
Reciproc Blue	62.67±7.0 ^a	63.209	.905	<.001*
Wave One Gold	63.33±12.11 ^a			
MicroMega One RECI	64.50±7.15 ^a			
EdgeOne Fire	124.33±10.23 ^b			

* $p < .05$ considered significant. Values with different superscript letters differ significantly (Tukey's post hoc test, $p < .05$).

Table 2

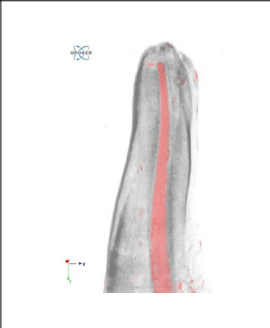

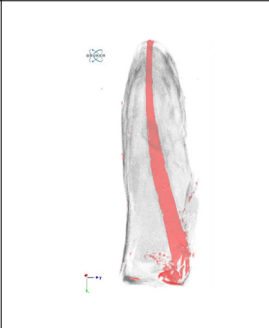

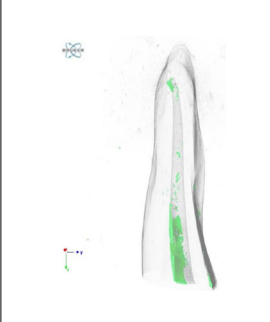
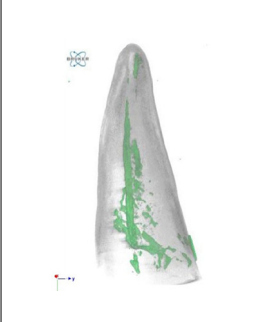

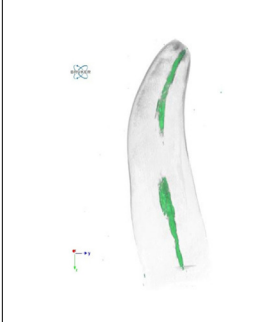
Groups	Reciproc Blue	WaveOne Gold	MicroMega One RECI	Edge One Fire
Pre-operative Micro-CT				
Post-operative Micro-CT				

Figure 1
Micro-CT of all comparative groups

Discussion

The evolution of endodontic instrumentation has profoundly influenced retreatment strategies. The transition from stainless-steel hand files to rotary NiTi systems, and more recently to reciprocating systems, has improved both efficiency and safety during canal preparation(8). Reciprocating instruments operate through alternating clockwise and counter-clockwise motions, which reduce cyclic fatigue and torsional stress while simplifying canal preparation with single-file techniques(9). These mechanical characteristics are particularly advantageous in retreatment procedures, where instruments must negotiate gutta-percha and resin-based sealers while maintaining the original canal anatomy. Maxillary molars were selected due to their complex canal morphology and higher reported failure rates(10). The mesiobuccal root is often characterized by curvatures and anatomical variations, representing a clinically chal-

lenging site for retreatment. Standardization to Vertucci Type I configuration ensured anatomical uniformity and minimized confounding variables(11). Micro-CT served as the gold standard for volumetric evaluation of remaining obturation material. Its non-destructive, high-resolution imaging allows precise quantification throughout the canal system, particularly in the apical third where complete removal of filling material is difficult(12).

Recent micro-CT retreatment studies have evaluated the performance of reciprocating systems. Ahmad A. Madarati et al. compared several reciprocating systems (WaveOne Gold, Reciproc Blue, and R-Motion) with rotary systems (Fanta AF-One and Tango-Endo) for removing calcium silicate-based fillings using micro-CT. Their findings indicated that reciprocating systems were more effective but required longer retreatment time, while the addition of Passive Ultrasonic Irrigation (PUI) significantly enhanced filling material removal.(13) Similarly, Fabio Luiz Ce-



cagno et al. reported using micro-CT that Reciproc, Reciproc Blue, and WaveOne Gold showed no significant difference in the removal of root canal filling materials, and none of the tested systems completely eliminated the obturation material.(7) WaveOne Gold was selected for initial canal preparation to ensure standardized canal shaping across all samples, as it is widely used and provides consistent and predictable preparation outcomes.

Four reciprocating systems incorporating proprietary heat-treated NiTi alloys were evaluated in this study. While all systems demonstrated the ability to remove obturation material within clinically acceptable timeframes, variations in cross-sectional design, tip activity, and metallurgical properties of NiTi alloys may influence retreatment performance.(13,14) Reciproc Blue and WaveOne Gold, with their safety-oriented tip designs and controlled cutting efficiency, allowed predictable canal negotiation. MicroMega One RECI, with its more aggressive cutting tip, facilitated deeper penetration of obturation material (15). EdgeOne Fire exhibited comparable performance, highlighting the potential of newer systems to provide effective retreatment outcomes (14).

Despite the use of EndoSolv R, complete removal of AH Plus sealer was not achieved in any group. This finding is consistent with previous studies demonstrating the strong adhesion and dimensional stability of epoxy resin-based sealers (16). The persistence of residual material, particularly in the apical third, highlights the limitations of mechanical instrumentation alone and supports the use of adjunctive approaches such as ultrasonic activation, supplementary finishing instruments, or improved irrigation strategies to enhance retreatment outcomes (17).

Among the tested systems, Reciproc Blue showed the lowest percentage of residual obturation material, indicating greater removal efficiency, although differences among systems were not

statistically significant except in the apical third in post treatment without GP. Its S-shaped cross-section with sharp cutting edges may facilitate effective engagement with gutta-percha and sealer, while deep flutes aid in coronal debris transportation. MicroMega One RECI demonstrated comparable efficiency, possibly due to its asymmetric cutting tip and S-shaped middle region enabling apical penetration and debris evacuation.

WaveOne Gold exhibited slightly higher residual values, which may relate to its conservative parallelogram cross-section and semi-active tip. Although this design minimizes taper lock and enhances shaping safety, it may reduce cutting aggressiveness against hardened obturation materials. EdgeOne Fire showed comparatively higher residual values and required longer retreatment time. Subtle differences in flute depth and tip configuration may influence cutting efficiency and debris removal, particularly in the apical region.

Across all systems, the apical third consistently retained the highest amount of residual material. This observation reflects the anatomical challenges of this region, including narrow diameter, curvature, and accumulation of sealer. Even the most efficient systems were unable to achieve complete removal of obturation material, which is consistent with previous micro-CT retreatment studies. Clinically, residual material in the apical third may limit irrigant penetration and potentially harbor persistent microorganisms, which may compromise retreatment success.

Operative efficiency is also an important clinical consideration. Reciproc Blue, WaveOne Gold, and MicroMega One RECI demonstrated comparable mean working times, whereas EdgeOne Fire required a longer operative duration. These findings suggest that instrument design may influence both retreatment efficiency and procedure time.

Few limitations must be acknowledged.



Rotary instruments are available as both treatment and retreatment-specific files, with retreatment files incorporating active cutting tips and specialized flute designs to enhance removal of obturation materials, particularly in the apical third. In contrast, reciprocating files are primarily designed for canal shaping, and their geometries may limit efficiency in complete removal of obturation materials. Furthermore, the reciprocating systems evaluated are primarily designed as shaping instruments rather than specifically engineered retreatment files, which may influence their efficiency in the removal of obturating materials. Consequently, the observed outcomes should be interpreted within the context of their intended clinical application. The relatively small sample size restricts generalizability, and although adequate for statistical comparison, larger studies are needed to improve reliability. Furthermore, the exclusive use of AH Plus sealer and standardized specimen age may not fully represent clinical variability. To improve retreatment effectiveness and therapeutic application, future *in vivo* investigations with bigger sample numbers, a wider variety of sealers, and uniform specimen selection are advised. Future studies involving larger sample sizes, different sealers, and clinical conditions are recommended to further evaluate the retreatment performance of reciprocating systems.

Clinical implication

In the present *in vitro* study evaluating the efficacy of four reciprocating systems in removing obturation material from maxillary first molars, complete removal was not achieved by any of the tested systems, particularly in the apical third. This finding highlights the inherent anatomical complexities of the apical region, including canal curvature, apical ramifications, and isthmuses, which limit the mechanical action of instruments. The persistence of residual obturation material in this

region may act as a potential substrate for microbial retention and biofilm persistence, thereby compromising the effectiveness of retreatment procedures. Additionally, remnants of sealer and gutta-percha can hinder the penetration of irrigants and intracanal medications into dentinal tubules, reducing disinfection efficacy. However, it is important to consider that the presence of residual material does not necessarily equate to clinical failure, as successful outcomes are also influenced by adequate chemomechanical debridement and the host response. Therefore, while none of the reciprocating systems demonstrated complete removal, their relative efficacy should be interpreted in the context of their ability to enhance overall canal disinfection rather than achieve total material removal.

Conclusion

Within the constraints of this *in vitro* micro-CT study, none of the tested reciprocating systems completely removed the obturating material. However, Reciproc Blue and MicroMega One RECI demonstrated superior apical cleaning efficiency compared with WaveOne Gold and EdgeOne Fire. These findings emphasize that instrument design characteristics significantly influence retreatment efficacy, particularly in anatomically complex apical regions.

References

1. Rossi-Fedele G, Ahmed HMA. Assessment of root canal filling removal effectiveness using micro-computed tomography: a systematic review. *J Endod.* 2017;43:520-6.
2. Zarekar M, Satpute A, Zarekar M. Endodontic retreatment of a maxillary first molar with orthograde retrieval of a separated file by a combination of ultrasonic and file braiding techniques: a case report. *Cureus.* 2023;15:e50140.
3. Paiva RCT, Solda C, Vendramini F, Vanni JR, Marcon FB, Fornari VJ, et al. Regaining apical patency with manual and reciprocating instrumentation during retreatment. *Iran Endod J.* 2018;13:351.
4. Shekarchizade N, Shahpouri M, Avalin Charsooghi M, Spagnuolo G, Soltani P. Comparative

- evaluation of the effectiveness of different rotary systems in removal of root canal filling materials. *G Ital Endod.* 2022; 36(1):151-158.
- Alsilani R, Jadu F, Bogari DF, Jan AM, Alhazzazi TY. Single file reciprocating systems: a systematic review and meta-analysis of the literature: comparison of Reciproc and WaveOne. *J Int Soc Prev Community Dent.* 2016;6:402-9.
 - Gandhi PJ, Jobanputra LH, Prajapati MH, Aroori H. Exploration of uninstrumented areas and volumetric precision of ProTaper Ultimate versus ProTaper Next file systems: a micro-computed tomography study. *J Conserv Dent Endod.* 2025;28:515-21.
 - Cecagno F, De Martin A, Fontana C, Cavenago B, Nascimento W, Limoeiro A. Evaluation of the ability of 3 reciprocating instruments to remove obturation material: a micro-computed tomography study. *J Endod.* 2024;50:376-80.
 - Hülsmann M, Peters OA, Dummer PMH. Mechanical preparation of root canals: shaping goals, techniques and means. *Endod Topics.* 2005;10:30-76.
 - Yared G. Canal preparation using only one reciprocating instrument: a new concept. *Int Endod J.* 2008;41:339-44.
 - Dandache G, Aksoy U, Ozel MB, Orhan K. Anatomic comparison of contralateral maxillary second molars using high-resolution micro-CT. *Symmetry.* 2023;15:420.
 - Vertucci FJ. Root canal anatomy of the human permanent teeth. *Oral Surg Oral Med Oral Pathol.* 1984;58:589-99.
 - Swain MV, Xue J. State of the art of micro-CT applications in dental research. *Int J Oral Sci.* 2009;1:177-88.
 - Madarati A. Efficiency of reciprocating systems reciprocated at different angles in removing root canal fillings. *BMC Oral Health.* 2022;22:357.
 - Gambarini G, Galli M, Di Nardo D, Seracchiani M, Donfrancesco O, Testarelli L. Differences in cyclic fatigue lifespan between two different heat-treated NiTi endodontic rotary instruments: WaveOne Gold vs EdgeOne Fire. *J Clin Exp Dent.* 2019; 11(7):e609-e613.
 - Pedullà E. MicroMega One RECI system: shaping and retreatment efficiency. *J Endod.* 2022;48:602-10.
 - Alamoudi RA. Comparative evaluation of the efficacy of different solvents on the removal of endodontic bioceramic sealers: an in vitro study. *J Int Clin Dent Res Organ.* 2024;16:126-34.
 - Limoeiro AG, Braitt AH, Silveira Machado A, Bueno CE, Fontana CE, Freire LG, et al. Micro-computed tomography evaluation of filling material removal by three reciprocating systems with different thermal treatments. *G Ital Endod.* 2021;35:13-18